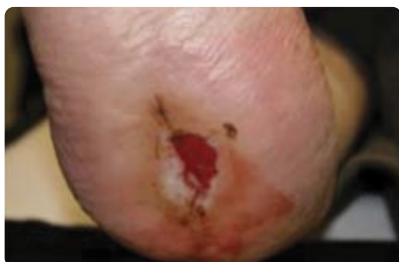


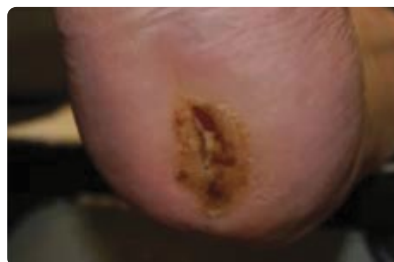## Diabetic Foot Ulcer

Howard Myles Kimmel, DPM, MBA, FACFAS

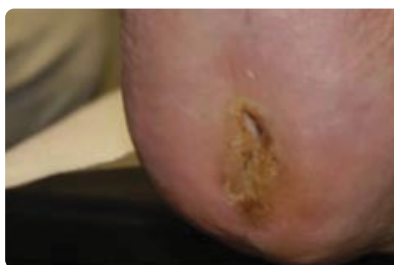- Cleveland, OH



Day of 1<sup>st</sup> Application



Week 2 Prior to 2<sup>nd</sup> Application. 60% Reduction



Week 4. 80% Reduction

Patient Data	
Age	55
Sex	Female
General Health Status	Charcot, Insulin Dependent Diabetes Mellitus
Wound	Diabetic Foot Ulcer present for 40 Weeks
Prior Treatments	Surgical Debridement/Partial Calcaneotomy, Non-Weightbearing, Dermagraft
Excellagen Treatment	Biweekly for 4 weeks

Excellagen is indicated for the management of wounds. Although many patients benefit from the use of the product, results may vary. Please see full prescribing information.