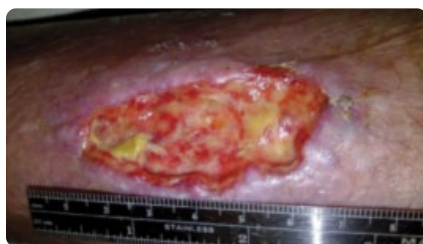

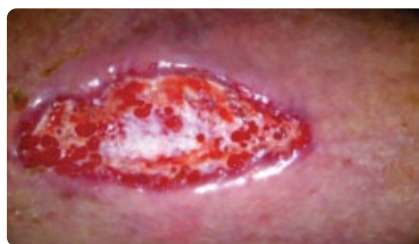Wound Dehiscence

Steven Smith, MD, Wellesley, MA

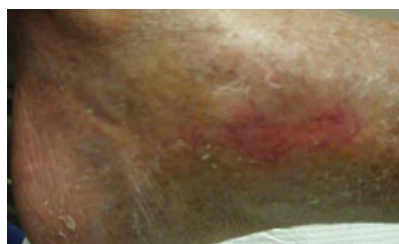"Extremely rapid healing of an extensive lower leg wound...the patient's high quality of life, including full, independent ambulation and driving ability, was restored." - Steven Smith, MD



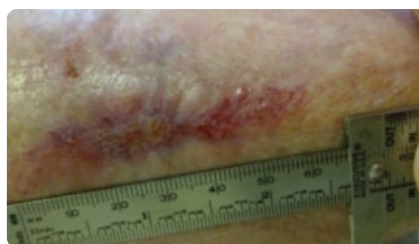
Pre-Treatment (16.2 cm²)
Wound Extends to Fascia



Week 4
Wound Fully Granulated



Week 9
(0.6 cm²)



Week 11
Fully Epithelialized

Patient Data	
Age	94
Sex	Female
General Health Status	Diabetes, Hypertension, MRSA
Initial Wound Status	Dehiscence with significant tissue necrosis following postoperative MRSA infection of Mohs surgical site
Surgical Site	Right lateral lower leg
Excellagen Treatment	Weekly for 4 weeks followed by twice daily application of Bacitracin ointment

Excellagen is indicated for the management of wounds. Although many patients benefit from the use of the product, results may vary. Please see full prescribing information.