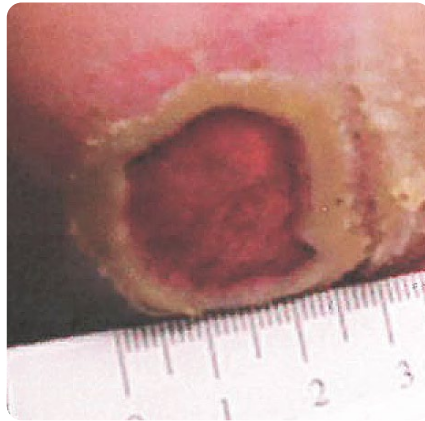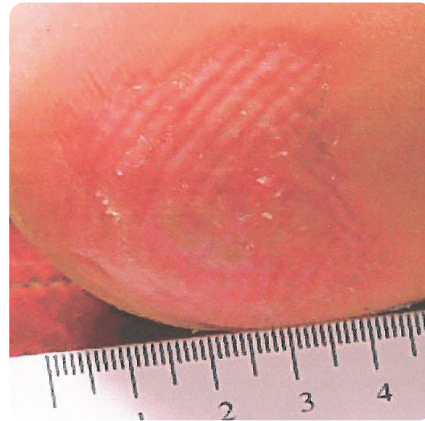


## Pressure Ulcer Curtis Long, DPM, Walla Walla, WA

“Noticed healing accelerated after first week – I was pleasantly surprised. I’m very pleased” – Dr. Curtis Long, DPM



**5/21/12: Wound Area 3.5 cm<sup>2</sup>  
Sharp debridement followed  
by Excellagen Application**



**7/16/12: Complete Wound  
Closure at 8 weeks  
Post-Treatment**

Subsequent to single Excellagen application, weekly dressing changes were performed using Aquacel hydrofiber dressing

Patient Data	
Age	68
Sex	Male
General Health Status	Obese, Wheelchair-Dependent, Type II Diabetes
Wound Location	Left Planter Heel-formed at pressure point (foot rest of wheelchair)
Wound Duration	16 Weeks
Prior Therapies	Debridement, Hydrophilic Wound Dressing, Pressure-Relieving Padding

Excellagen is indicated for the management of wounds. Although many patients benefit from the use of the product, results may vary. Please see full prescribing information.